

Initial clinical experience with Myxo-ETlogix* mitral valve repair ring

P. M. McCarthy, MD,^a E. C. McGee, MD,^a V. H. Rigolin, MD,^b Q. Zhao, MD,^b H. Subačius, MA,^c A. L. Huskin, RN,^c S. Underwood, RN,^a B. J. Kane, RDCS,^b I. Mikati, MD,^b G. Gang, MD,^a and R. O. Bonow, MD^b

Objective: Complexity of mitral valve repair for myxomatous disease has led to low adoption. We report initial experience with a new ring designed specifically for myxomatous disease, the Myxo-ETlogix (Edwards Lifesciences LLC, Irvine, Calif).

Methods: From March 15, 2006, through November 19, 2007, 129 patients underwent mitral valve surgery for pure myxomatous disease, and 124 valves (96.1%) were repaired. The Myxo-ETlogix ring was used in 100 cases and the Physio ring (Edwards) in 24. The Myxo-ETlogix design includes a 3-dimensional shape to reduce systolic anterior motion and a larger orifice to accommodate elongated leaflets and decrease need for sliding plasty. Direct mitral valve measurements were made. Sizing was based on A2 height, and choice of ring type was based on unresected leaflet heights.

Results: There was no operative mortality or lasting perioperative morbidity. The Myxo-ETlogix group had taller A2, P1, P2, and P3 leaflet segments than the Physio group ($P \leq .003$). Only 1 sliding plasty was performed for asymmetry in the Myxo-ETlogix group. Pre-discharge and follow-up echocardiograms ($n = 338$ in 124 patients) disclosed transient nonobstructive chordal systolic anterior motion in 3 echocardiograms in 3 patients. No patients had 2+ or greater mitral regurgitation. At discharge, 5.7% had 1+ mitral regurgitation; this proportion was 17.3% at last follow-up (mean 6.1 ± 4.4 months).

Conclusion: In initial experience with the Myxo-ETlogix ring, nonobstructive systolic anterior motion has been rare and obstructive systolic anterior motion not observed. Ongoing prospective echocardiographic and clinical studies will elucidate the role of this etiology-specific ring.

From the Bluhm Cardiovascular Institute, Division of Cardiothoracic Surgery,^a Cardiology,^b and Clinical Trials Unit,^c Northwestern Memorial Hospital, Chicago, Ill.

Read in part at the Eighty-seventh Annual Meeting of The American Association for Thoracic Surgery, Washington, DC, May 5–9, 2007.

P.M.M. is the inventor of the Myxo-ETlogix ring and receives royalties. R.O.B. and P.M.M. are consultants for Edwards Lifesciences LLC.

*Myxo-ETlogix is a trade name of Edwards Lifesciences LLC, Irvine, Calif.

Received for publication June 15, 2007; revisions received Dec 21, 2007; accepted for publication Feb 12, 2008.

Address for reprints: Patrick M. McCarthy, MD, Northwestern University, Division of Cardiothoracic Surgery, 201 E Huron St, Suite 11-140, Chicago, IL 60611-2908 (E-mail: pmccart@nmh.org).

J Thorac Cardiovasc Surg 2008;136:73-81
0022-5223/\$34.00

Copyright © 2008 by The American Association for Thoracic Surgery

doi:10.1016/j.jtcvs.2008.02.013

Mitral valve (MV) prolapse is common, occurring in 1% to 2.5% of the population.¹ Myxomatous mitral regurgitation (MR) is characterized by elongation and thickening of the valve leaflets with annular and dilatation prolapse (Carpentier type II).² Numerous studies have demonstrated that mitral repair generally gives a more favorable result than does MV replacement, but because of the complexity of the pathology and therefore the procedure required, it is performed in fewer than 50% of cases according to data from the United States and Europe.³⁻⁶ Furthermore, the considerable interpatient variability has required the surgeon to approach valve repair as an art, and valve repair has been concentrated such that a minority of surgeons perform the majority of repairs. Consequently, it has been difficult for a low- or medium-volume mitral repair surgeon to develop the numerous skills necessary for successful repair, considering the wide variety of surgical techniques that may be required for complex repairs.

An additional repair problem specific to myxomatous disease is the development of systolic anterior motion (SAM), which has been reported in 2% to 16% of patients after mitral repair.⁷⁻¹⁰ Transient SAM may be seen during first weaning from cardiopulmonary bypass and may be easily treated by volume infusion from the pump to increase the systemic blood pressure (afterload) if the patient is hypotensive and vasodilated and by stopping positive inotropes. More troublesome is persistent SAM, which may require additional medical or surgical therapy. SAM is precipitated by

Abbreviations and Acronyms

MR = mitral regurgitation
 MV = mitral valve
 SAM = systolic anterior motion

elongated leaflets and may cause left ventricular outflow tract obstruction and residual or recurrent MR. SAM may be caused by a short distance between the point of leaflet coaptation to the nearest point on the ventricular septum, which may be seen when the posterior leaflet is too tall or the annuloplasty ring placed is too small.^{7,8} An elongated anterior leaflet may also contribute to SAM, and numerous techniques can be used to avoid or eliminate SAM, such as shortening the anterior leaflet, creating a double orifice (edge-to-edge approximation), or even myectomy.^{2,11-16} Reducing the height of the posterior leaflet (sliding plasty) is the most common technique.^{2,10,17} Although some would argue that SAM may be managed medically with long-term β -blocker therapy and a low late need for reoperation, persistent SAM may be associated with continuing MR, and a young patient requiring long-term β -blocker therapy has had an imperfect operation.^{18,19} In an age when surgery is being performed early, in symptom-free patients, this result is less than ideal.¹ Ideally, the repair procedure would avoid SAM altogether and not require long-term medical management.

We sought to develop a new MV repair ring designed to accommodate the specific pathologic conditions of myxomatous disease. This etiology-specific ring, the Myxo-ETlogix (Edwards Lifesciences LLC, Irvine, Calif) ring has a larger orifice than does a Physio (Edwards Lifesciences) ring (which is based on normal anatomy) to accommodate the elongated leaflets. It also has a 3-dimensional shape that moves the coaptation point away from the septum (increasing the distance between the point of leaflet coaptation to the nearest point on the ventricular septum), thereby reducing the risk of SAM.^{8,14} Because this etiology-specific ring has a larger orifice, a secondary advantage would be that extensive leaflet reconstruction to reduce the size of the leaflets back to “normal” (sliding plasty) would not be needed, or at least would be needed much less frequently. This would reduce the complexity of myxomatous valve repair and ideally make it more generalizable. Furthermore, the larger orifice leads to a low or normal gradient. This is the first report of the concepts behind the new Myxo-ETlogix, the impact that it had on our use of other mitral repair rings and techniques, and the initial clinical results.

Materials and Methods**Patient Characteristics**

Patient information and follow-up data were obtained from the prospectively maintained cardiac surgery outcomes registry of the

Bluhm Cardiovascular Institute, which was approved by the Northwestern University Institutional Review Board for use in research.

The study ran from the date of first use of Myxo-ETlogix (March 15, 2006) until the date of 100th Myxo-ETlogix implant (November 19, 2007). For the purposes of this study, we analyzed only those patients with MR caused by isolated myxomatous degenerative MV disease (n = 129). The diagnosis of myxomatous disease was determined by echocardiographic and surgical findings of elongated MV leaflets with prolapse (type II). Patients were excluded if they had rheumatic valve disease, ischemic valve disease, cardiomyopathy, endocarditis, or mixed pathology. Among the 129 myxomatous MR cases, MV repair was performed in 124 patients (96.1%), and MV replacement was performed in 5 patients (3.9%). These 5 patients had ages of 65, 72, 74, 78, and 84 years, and all had annular and leaflet

calcification. Patients included in this analysis were operated on by two surgeons at a single institution, Northwestern Memorial Hospital.

In the repair group, 100 patients received the Myxo-ETlogix annuloplasty ring, which is a Food and Drug Administration–approved device for patients undergoing MV repair.

During the same period, the Carpentier–Edwards Physio ring was used to repair 24 valves in patients with myxomatous MV disease. Thus 80.6% of the patients with myxomatous disease underwent repair with the Myxo-ETlogix ring, and 19.4% underwent repair with a Physio ring. According to our practice, all patients in the group were prospectively followed up by a specific valve nurse who was available to answer patient questions, arrange follow-up visits, and facilitate entry into prospective 3-dimensional echocardiographic and other imaging studies. The characteristics of the patients who received the Myxo-ETlogix ring are compared with those of the patients who received a Physio ring in Table 1. Overall, the age of the patients was 57 ± 13 years, and the Myxo-ETlogix patients were younger ($P = .047$). The Myxo-ETlogix patients had more MR (97% with 4+, $P < .001$). Other significant differences between the groups included smaller body mass index and more white patients in the Myxo-ETlogix group (patient self-report), whereas patients in the Physio group were more likely to have chronic obstructive pulmonary disease. The 5 patients who underwent MV replacement were significantly older than the 124 repair patients ($P < .001$), and their operative findings precluded safe, durable MV repair. All these patients underwent valve replacement with a bioprosthetic bovine pericardial valve. In keeping with the trend toward early repair in patients with myxomatous MV disease, most of the patients in the repair group were in New York Heart Association functional class I or II (81.4%).

Characteristics of the Myxo-ETlogix Ring

The Myxo-ETlogix ring was designed as a complete annular remodeling ring with etiology-specific variations from the Physio ring (Figure 1).²⁰ The anteroposterior dimension of the ring was increased 29% to accommodate elongated myxomatous leaflets. Depending on the exact size of the ring, this led to an increase in anteroposterior diameter of 5 to 8 mm, designed to correspond to typical reduction in posterior leaflet height in patients who undergo sliding plasty. Rather than the surgeon performing extensive reconstruction to reduce the height of the posterior leaflet by 5 to 8 mm, instead the ring pulls the posterior leaflet down by a corresponding amount. This also creates a 16% increase in the total orifice area for the Myxo-ETlogix ring. The largest anteroposterior diameter of a size 40 Physio ring is 27.2 mm, which corresponds most closely to a size 32 Myxo-ETlogix ring (28.0 mm). A size 40 Myxo-ETlogix

TABLE 1. Preoperative patient characteristics by annuloplasty type

	Total (N = 124)	Physio (n = 24)	Myxo-ETlogix (n = 100)	P value
Age (y)				.047*
Mean ± SD	57.4 ± 13.4	62.2 ± 12.1	56.2 ± 13.5	
Range	22–85	41–81	22–85	
Male (No.)	76 (61.2%)	14 (58.3%)	62 (62.0%)	NS
Body mass index (kg/m ²)				.006†
Mean ± SD	25.4 ± 4.5	27.6 ± 3.9	24.9 ± 4.5	
Range	15.1–39.5	20.2–34.2	15.1–39.5	
White race (No.)	103 (83.1%)	16 (66.7%)	87 (87.0%)	.017
Previous cardiac surgery (No.)	1 (0.8%)	0 (0.0%)	1 (1.0%)	NS
Comorbidities (No.)				
Previous myocardial infarction	2 (1.6%)	1 (4.2%)	1 (1.0%)	NS
Congestive heart failure	16 (12.9%)	5 (20.8%)	11 (11.0%)	NS
Coronary artery disease	19 (15.3%)	4 (16.7%)	15 (15.0%)	NS
Diabetes	3 (2.4%)	0 (0.0%)	3 (3.0%)	NS
Hypertension (systemic)	48 (38.7%)	13 (54.2%)	35 (35.0%)	.083
Hypertension (pulmonary)	65 (52.9%)	13 (54.2%)	52 (52.0%)	NS
Renal failure	0 (0.0%)	0 (0.0)	0 (0.0)	NS
Chronic obstructive pulmonary disease	8 (6.5%)	4 (16.7%)	4 (4.0%)	.045‡
Hyperlipidemia	40 (32.3%)	9 (37.5%)	31 (31.0%)	NS
Atrial fibrillation or flutter	26 (21.0%)	7 (29.2%)	19 (19.0%)	NS
New York Heart Association functional class (No.)				NS
I	35 (28.2%)	4 (16.7%)	31 (31.0%)	
II	66 (53.2%)	13 (54.2%)	53 (53.0%)	
III–IV	23 (18.6%)	7 (29.2%)	16 (16.0%)	
Prolapse (No.)				NS
Anterior	8 (6.5%)	2 (8.7%)	6 (6.0%)	
Posterior	83 (67.5%)	19 (82.6%)	64 (64.0%)	
Anterior and posterior	32 (26.0%)	2 (8.7%)	30 (30.0%)	
Preoperative echocardiographic mitral regurgitation (No.)				<.001
2+	2 (1.6%)	2 (8.3%)	0 (0.0%)	
3+	7 (5.7%)	4 (16.7%)	3 (3.0%)	
4+	115 (92.7%)	18 (75.0%)	97 (97.0%)	
LV ejection fraction (%)				NS
Mean ± SD	59.4% ± 7.5%	60.7% ± 7.0%	59.1% ± 7.6%	
Range	35%–80%	50%–80%	35%–75%	
LV end-systolic dimension (cm)				NS
Mean ± SD	3.6 ± 0.6	3.6 ± 0.6	3.6 ± 0.6	
Range	2.1–5.1	2.3–4.4	2.1–5.1	
LV end-diastolic dimension (cm)				NS
Mean ± SD	5.5 ± 0.7	5.5 ± 0.6	5.5 ± 0.7	
Range	3.9–7.1	4.3–6.5	3.9–7.1	

NS, not significant ($P > .20$); LV, left ventricular. *Squared transformation. †Natural log transformation. ‡Fisher exact test.

ring has an anteroposterior diameter of 35.0 mm. The Myxo-ETlogix ring was only available in sizes 26 through 36 until mid November 2006, when sizes 38 and 40 became available but sizes 26 and 28 became unavailable. This shortage was due to production of a limited quantity of early rings.

In addition to accommodating the larger leaflets, the Myxo-ETlogix ring was designed to move the coaptation point down, and also away from the septum, by means of a 4-mm shape change centered at the P2 region, pulling the ring into the left atrium (Figure 1) and resulting in an increase in the distance between the point of leaflet coaptation to the nearest point on the ventricular septum. The net

effect of these two changes is to pull the coaptation point down and away from the septum.

Operative Techniques

Operative techniques were largely based on Carpentier’s time-tested concepts of resection of the prolapsing segment, chordal transfer if necessary, leaflet reconstruction, and complete remodeling annuloplasty ring.^{3,20} The Myxo-ETlogix ring was used for patients with elongated anterior leaflets or tall remaining posterior leaflet segments after resection. If the remaining posterior and anterior leaflets were normal after resection, then a Physio ring was used. Repair techniques

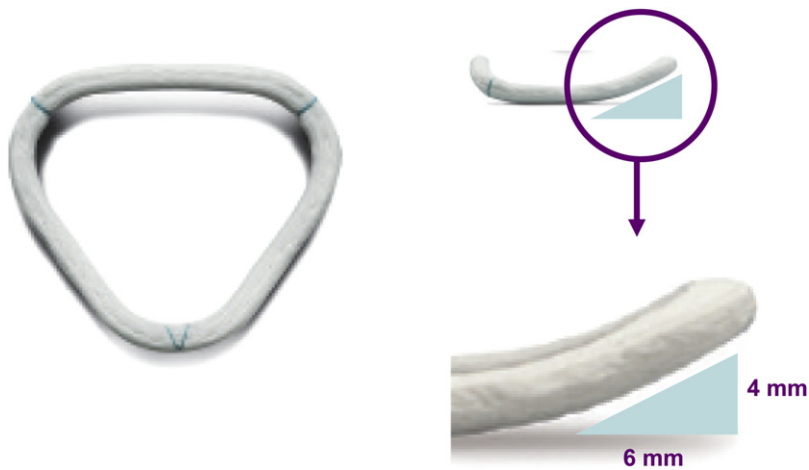

Figure 1. Myxo-ETlogix ring designed for patients with leaflet elongation historically treated with sliding plasty with risk of systolic anterior motion. Ring has longer anteroposterior diameter (typically 6 mm) to accommodate larger leaflets, corresponding to typical posterior leaflet height reduction from sliding plasty. P2 segment of ring has 4-mm displacement into annulus. Net effect of these two changes moves coaptation point down and away from septum, reducing risk of systolic anterior motion.

for both groups included leaflet resection, chordal transfer, commissuroplasty, and ring annuloplasty. No artificial chords were used in any patients. Before the Myxo-ETlogix ring was available, sliding annuloplasty was performed in 38% of cases of myxomatous disease (according to our database) when the remaining posterior segments were longer than 20 mm by visual inspection (not by direct measurement, which was not yet available) and sometimes when the posterior leaflet was shorter than 20 mm but there was a wide resection.

Concomitant cardiac surgical procedures (Table 2) included a maze procedure in 31 patients (25%), tricuspid valve annuloplasty in 12 patients (9.7%), coronary artery bypass grafting in 17 patients (13.7%), and aortic valve replacement in 3 patients (2.4%). There was no difference in concomitant procedures between the Physio and Myxo-ETlogix groups, but the ring size used in the Myxo-ETlogix group was larger ($P = .001$). The 1 patient (in the Myxo-ETlogix group) who underwent sliding plasty had an unresected remnant P2 height of 27 mm and a P3 height of 16 mm. Because of the extensive size discrepancy and a wide resection (22 mm), the height of the remaining P2 was reduced with a short sliding plasty. A second pump run was performed in 2 cases (1.6%) because of residual MR (1+–2+), with conversion from repair to replacement in an 84-year-old patient and successful additional leaflet repair in another patient.

Direct MV Measurements and Choice of Myxo-ETlogix Versus Physio Ring

Direct measurements of the MV were taken with a custom-designed set of measuring calipers. These distance measurements included commissure-to-commissure, trigone-to-trigone, and heights of the leaflet at P1, P2, P3, and A2 segments (Figure 2). Other measurements included width of the resected segment, width of the annulus after compression sutures, height of the middle segment of the posterior leaflet after reconstruction when applicable, and overlaps at P1, P2, P3, A1, A2, and A3. The results of these measurements are depicted in Figure 2. Table 3 compares the measures in patients with Myxo-ETlogix rings with those of patients with Physio rings. Measurements were available for 98 of 100 patients in the Myxo-ETlogix group and 22 of 24 patients in the Physio group.

Ring size was chosen according to A2 height. The measurement was referenced to a chart of the anteroposterior diameter of Myxo-

ETlogix and Physio rings. Ring size was true sized to A2 height in most cases. Occasionally, a larger Myxo-ETlogix ring was chosen because of an unusually tall (>20 mm) posterior leaflet, a smaller Myxo-ETlogix ring was chosen if there was a short posterior leaflet (<12 mm), or another size was chosen if the closest ring size was not available. Other measurements or judgments (commissure-to-commissure, trigone-to-trigone, anterior leaflet surface area) were not used for sizing.

The Physio ring was used for the subset of patients who had what Carpentier classifies as “fibroelastic deficiency.”²¹ This group tended to be older, with associated comorbidities such as hypertension and chronic obstructive pulmonary disease, and the pathologic characteristics typically consisted of ruptured chords at the P2 segment with normal lengths of P1, P3, and A2. The pathology at P2 was resected, and the remaining valve leaflet lengths were therefore normal, so the Physio ring was chosen as a design based on normal valve anatomy.¹⁰ Patients who received a Myxo-ETlogix ring consisted of those with Barlow disease and those with lengthening of unresected segments of the leaflet, the anterior leaflet, or both. Most patients did not fall into two distinct categories (Barlow disease vs fibroelastic deficiency) and instead had more intermediate leaflet length, as depicted in Figure 2.

Echocardiographic Techniques

MR was assessed as follows: none or trivial, 0; mild, 1+; moderate, 2+; moderate to severe, 3+; and severe, 4+. Nonobstructive (chordal) SAM was defined as anterior motion of the MV or subvalvular apparatus without an elevation of the peak velocity or a late peaking velocity profile in the Doppler waveforms in the left ventricle or left ventricular outflow tract. Echocardiography was performed in 100% of patients intraoperatively, at discharge, and, according to our usual practice, at approximately 1 month and between 3 and 6 months after surgery, annually, and any other time as clinically indicated.

Statistical Analysis

Demographic and clinical patient characteristics in the Physio and Myxo-ETlogix groups were compared with t tests for continuous variables and χ^2 tests for categorical variables. Group differences in intraoperative variables were evaluated with the same

TABLE 2. Operative results

	Total (N = 124)	Physio (n = 24)	Myxo-ETlogix (n = 100)	P value
Ring size (mm)				.001
Mean ± SD	33.0 ± 3.4	31.1 ± 2.6	33.5 ± 3.4	
Range	26–40	26–36	26–40	
Resection (No.)	110 (88.7%)	20 (83.3%)	90 (90.0%)	NS
Width of resection (mm)				<.001
Mean ± SD	15.5 ± 6.4	11.3 ± 3.5	16.6 ± 6.5	
Range	7–36	7–20	7–36	
Sliding plasty (No.)	0 (0.8%)	0 (0.0%)	1 (1.0%)	NS
Chordal transfer (No.)	20 (16.1%)	1 (4.2%)	19 (19.0%)	.119*
Crossclamp time (min)				.195†
Mean ± SD	88.1 ± 22.7	83.5 ± 24.1	89.2 ± 22.3	
Range	52–169	52–138	55–169	
Cardiopulmonary bypass time (min)				NS
Mean ± SD	104.7 ± 26.1	101.0 ± 26.5	105.6 ± 26.0	
Range	67–190	67–159	67–190	
Commissuroplasty (No.)	7 (5.7%)	0 (0.00%)	7 (7.0%)	NS
Concomitant procedures (No.)				
Coronary artery bypass grafting	17 (13.7%)	3 (12.5%)	14 (14.0%)	NS
Atrial valve replacement	3 (2.4%)	0 (0.00%)	3 (3.0%)	NS
Tricuspid valve annuloplasty	12 (9.7%)	1 (4.2%)	11 (11.0%)	NS
Maze	31 (25.0%)	8 (33.3%)	23 (23.0%)	NS
Postoperative				
Mortality, infection, myocardial infarction, or acute renal failure (No.)	0 (0.0%)	0 (0.0%)	0 (0.0%)	NS
Reoperation for bleeding (No.)	1 (0.8%)	0 (0.0%)	1 (1.0%)	NS
Cerebrovascular accident (No.)	1 (0.8%)	0 (0.0%)	1 (1.0%)	NS
Hospital stay (d)				NS
Mean ± SD	5.8 ± 2.9	6.0 ± 2.6	5.6 ± 2.9	
Range	3–24	4–15	3–24	
Intraoperative echocardiography				
Mitral regurgitation (No.)				NS
0	121 (97.6%)	23 (95.8%)	98 (98.0%)	
1+	3 (2.4%)	1 (4.2%)	2 (2.0%)	
Mean gradient (mm Hg)				NS
Mean ± SD	3.1 ± 1.5	3.3 ± 1.9	3.0 ± 1.4	
Range	0.6–10.0	1.4–10.0	0.6–9.0	
Predischarge echocardiography				
Mitral regurgitation (No.)				NS
0	115 (92.7%)	23 (95.8%)	92 (93.9%)	
1+	7 (5.7%)	1 (4.2%)	6 (6.1%)	
Mean gradient (mm Hg)				.134†
Mean ± SD	3.3 ± 1.4	3.7 ± 1.7	3.2 ± 1.4	
Range	1.2–8.6	1.5–8.0	1.2–8.6	

NS, Not significant. *Fisher exact test. †Natural log transformation.

methodology. Continuous variables were appropriately transformed if a better approximation of normal distribution could be achieved. Fisher exact test was used for comparisons of categorical variables with a minimum cell count of 5 or less.

Results

Postoperative complications were low, with no deaths, no infections, **no perioperative infarctions**, 1 reoperation for bleeding (0.8%), and 1 stroke on postoperative day 3 from atrial

fibrillation that resolved before discharge. Follow-up was 100% complete, and there were no late deaths.

Predischarge and follow-up echocardiograms totaled 338. No MR or trivial MR was present at discharge in 92.7% of patients, and 1+ was present in 5.7% (Table 2). Mean gradient at discharge showed a trend toward being higher in the Physio group (3.7 ± 1.7 mm Hg vs 3.2 ± 1.4 mm Hg, P = .134, natural log transformation to normalize the data). At most recent follow-up (mean 6.1 ± 4.4 months)

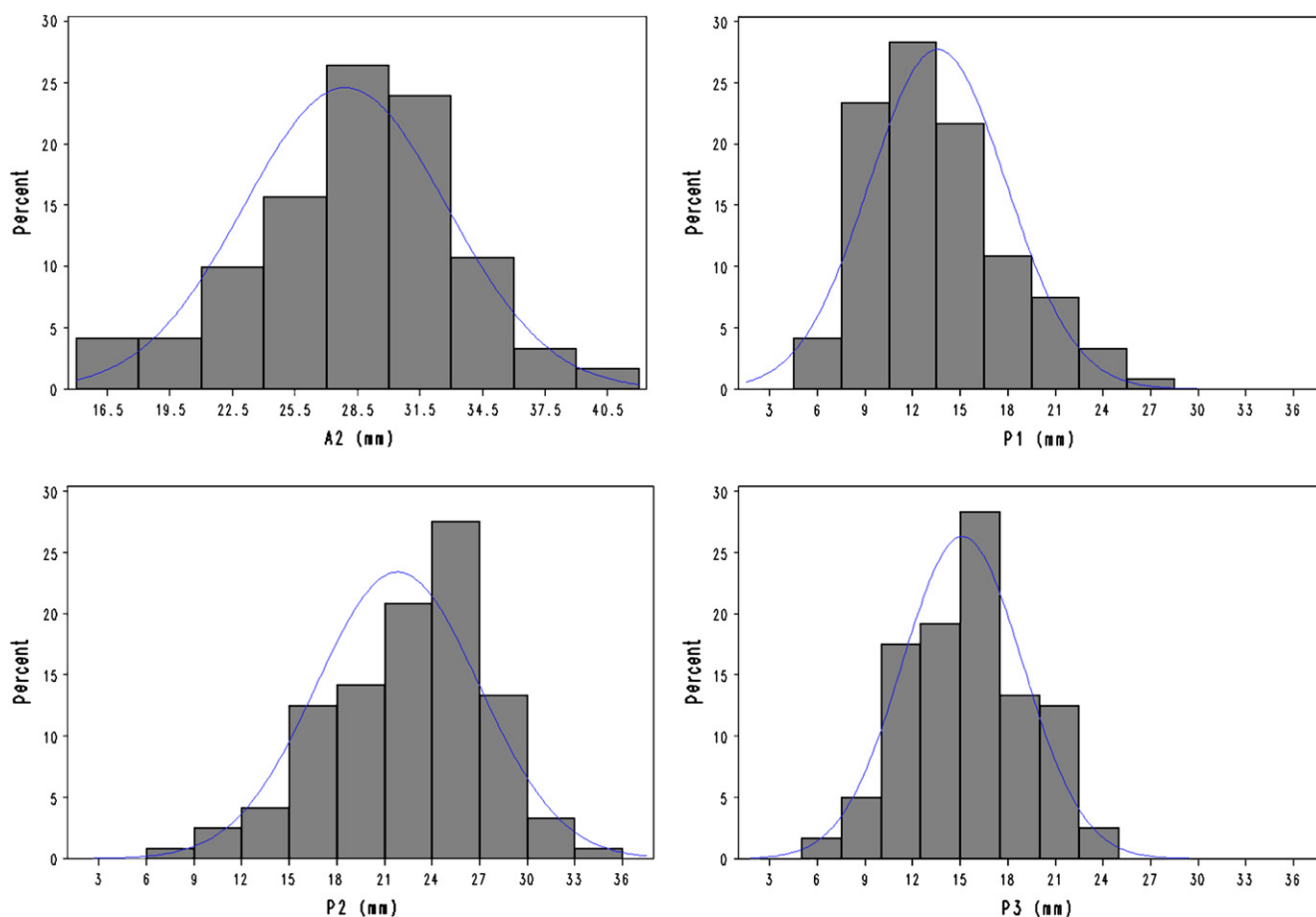


Figure 2. Direct measurement with custom calipers provided quantitative data on leaflet length in different segments documenting elongated leaflets in bell-shaped frequency curve. In particular, A2 height was very elongated; this was used to choose appropriate ring type (Physio ring vs Myxo-ETlogix ring) and ring size.

1+ MR was present in the Physio group in 1 patient (10%) and in the Myxo-ETlogix group in 16 patients (18%, differences from baseline and between groups not significant). There was no significant difference between MR at discharge and last follow-up. No patients had 2+ or greater MR.

After surgery, no obstructive SAM was seen, and nonobstructive chordal SAM was inconsistently seen in 3 patients. In 1 patient (with a 32-mm Myxo-ETlogix valve), SAM was first detected 14 days after discharge, but subsequent echocardiograms on days 82, 214, and 397 had negative results. In a second patient (with a 36-mm Myxo-ETlogix valve), there was no SAM early (pre-discharge or day 12 after discharge), SAM was recorded on day 160 after discharge, and at 1-year follow-up there was no SAM. In a third patient (with a 34-mm Physio ring), discharge echocardiography showed chordal SAM; this patient has not yet returned for follow-up. Transient intraoperative SAM shortly after weaning from bypass was uncommon (3 patients), depended on volume status and blood pressure, and never required a sec-

ond pump run or revision. One patient (with a 28-mm Myxo-ETlogix valve with commissuroplasty) had an early uneventful course after repair, with a low gradient (3.5 mm Hg), but had an intense, generalized inflammatory reaction, including both mitral leaflets, and required reoperative MV replacement for mitral stenosis 13 months after repair. Table 2 summarizes operative results for both groups.

Discussion

Overall, in an age of early repair for myxomatous disease, our results demonstrated a safe operation with low morbidity, a high rate of repair (96%), and excellent early results with little residual or recurrent MR (none at least 2+). We have found clinical benefit in precise anatomic measurement of the pathologic tissue, and these data drive our choice of ring size and type of ring prosthesis. This has led to predictable coaptation of the leaflets, without rings or residual leaflet heights we considered too small or too big. Our data indicate that although some patients' leaflets fall into the extremes of

TABLE 3. Direct preoperative and postoperative mitral valve measurements

Measurement (mm)	Total	Physio (n = 22)	Myxo-ETlogix (n = 98)	P value
A2				<.001
Mean ± SD	27.9 ± 4.9	23.7 ± 5.2	28.9 ± 4.3	
Range	15-41	17-34	15-41	
P1				<.001
Mean ± SD	13.6 ± 4.3	10.6 ± 2.9	14.3 ± 4.3	
Range	6-27	6-20	6-27	
P2				.003
Mean ± SD	21.9 ± 5.1	19.0 ± 4.6	22.5 ± 5.0	
Range	7-34	9-30	7-34	
P-middle*				<.001
Mean ± SD	14.6 ± 2.9	12.3 ± 1.9	15.1 ± 2.8	
Range	8-23	10-16	8-23	
P3				<.001
Mean ± SD	15.1 ± 3.8	12.5 ± 2.6	15.7 ± 3.8	
Range	6-24	8-18	6-24	
Cusp-to cusp				.007
Mean ± SD	38.1 ± 6.0	35.0 ± 4.3	38.8 ± 6.2	
Range	27-51	27-45	27-51	
Trigone-to-trigone				.023
Mean ± SD	24.6 ± 4.2	22.8 ± 3.4	25.0 ± 4.3	
Range	14-36	16-28	14-36	
P2 overlap				.003
Mean ± SD	6.5 ± 1.9	5.4 ± 1.4	6.8 ± 1.9	
Range	2-13	4-9	2-13	
A2 overlap				.070
Mean ± SD	5.7 ± 1.9	5.0 ± 1.6	5.8 ± 1.9	
Range	2-11	3-9	2-11	

*P-middle is the height of the leaflet after P2 resection and reconstruction.

Barlow disease versus fibroelastic deficiency, most patients' leaflet lengths fall somewhere between these extremes. Although an artistic, creative approach to complex valve problems with many different techniques is still valuable, we hope to move toward a more standardized, generalizable, reproducible repair that will lead to higher repair rates. Our current approach includes three steps: (1) trapezoidal resection (mean 15.5 ± 6.4 mm) of prolapsing posterior leaflet segments with chordal transfer to extensive anterior prolapsing segments if needed, (2) ring choice and sizing that is based on A2 and remaining posterior leaflet heights, and (3) complete remodeling annuloplasty with a Physio ring for normal remaining leaflets or with a Myxo-ETlogix ring for elongated leaflets. Although sliding plasty (and other complex techniques) should not be forgotten, in our institution we reduced the use of sliding plasty from 38% before this series to less than 1% in this experience. After reconstruction, the ratio of A2 height to posterior leaflet was 1.9 in both groups, which is thought to be optimal. Others routinely use resection without sliding plasty, but SAM does appear to be more common in those series than in ours (2.4% transient nonobstructive SAM and SAM without left ventricular outflow tract obstruction).^{18,22}

Quantitative data, other than from echocardiograms, have been hard to find in mitral repair series. Use of the Adams "ink test" and direct measurement of valve segments should help standardize our results and make it easier to compare results from different series.²³⁻²⁵ All these points are important, because we now see symptom-free patients for whom the guidelines recommend repair at experienced centers if there is a greater than 90% chance of repair without residual MR.^{1,24,25}

Large annuloplasty rings have been recommended for patients with Barlow disease.⁷ We agree that this is an important consideration, and more practical than bileaflet resection or reconstruction to reduce leaflet height. The new Myxo-ETlogix ring, designed for these patients, is significantly larger than existing commercial remodeling rings. Barlow disease is not a distinct entity in most cases, however, and even histologic studies have shown a large group of disorders intermediate between Barlow disease and fibroelastic deficiency.²¹ Whereas some surgeons may describe Barlow disease in 1% of patients, others may use that term to describe 50% of their patients with degenerative disease. Furthermore, our data show that some patients may have an elongated A2 segment but normal posterior segments, or vice versa. The

choice of a large ring thus is variable by surgeon. Although the average A2 height in our series (29 mm) corresponds most closely to a 34 Myxo-ETlogix ring, larger than the largest Physio ring (27 mm), we commonly used smaller Myxo-ETlogix rings instead of large Physio rings because of the perceived benefit of the 4-mm P2 displacement with the Myxo-ETlogix ring to reduce the risk of SAM. Whether it is the P2 displacement or the large size of the Myxo-ETlogix ring that accounts for our low incidence of SAM is not yet clear.

Study Limitations

This was a nonrandomized study of the initial use of a new commercially available ring, but not all ring sizes were available during the study period. The inventor of the ring was the surgeon in the vast majority of cases, and we attempted to reduce this bias with direct quantitative measurements and standard echocardiographic reporting. The data in all tables and figures therefore represent unbiased measurements and clinical results. A randomized trial is certainly feasible but would be best performed at another institution, albeit with experienced surgeons.

In summary, a new ring was introduced with a change in our clinical practice. The result was simpler MV repair procedures, rare nonobstructive SAM, and excellent clinical and echocardiographic results. Further confirmation at other centers is pending, and late echocardiographic follow-up is ongoing.

References

- American College of Cardiology/American Heart Association Task Force on Practice Guidelines, Society of Cardiovascular Anesthesiologists, Society for Cardiovascular Angiography and Interventions, Society of Thoracic Surgeons, Bonow RO, Carabello BA, et al. ACC/AHA 2006 guidelines for the management of patients with valvular heart disease: a report of the American College of Cardiology/American Heart Association Task Force on Practice Guidelines (writing committee to revise the 1998 Guidelines for the Management of Patients With Valvular Heart Disease): developed in collaboration with the Society of Cardiovascular Anesthesiologists; endorsed by the Society for Cardiovascular Angiography and Interventions and the Society of Thoracic Surgeons [Published erratum appears in *Circulation*. 2007;115(15):e409]. *Circulation*. 2006;114:e84-231.
- Adams DH, Anyanwu AC, Rahmanian PB, Filsoufi F. Current concepts in mitral valve repair for degenerative disease. *Heart Fail Rev*. 2006;11:241-57.
- Braunberger E, Deloche A, Berrebi A, Abdallah F, Celestin JA, Meimoun P, et al. Very long-term results (more than 20 years) of valve repair with Carpentier's techniques in nonrheumatic mitral valve insufficiency. *Circulation*. 2001;104(12 Suppl):I8-11.
- Iung B, Baron G, Butchart EG, Delahaye F, Gohlke-Barwolf C, Levang OW, et al. A prospective survey of patients with valvular heart disease in Europe: The Euro Heart Survey on Valvular Heart Disease. *Eur Heart J*. 2003;24:1231-43.
- Savage EB, Ferguson TB Jr, DiSesa VJ. Use of mitral valve repair: analysis of contemporary United States experience reported to the Society of Thoracic Surgeons National Cardiac Database. *Ann Thorac Surg*. 2003;75:820-5.
- Suri RM, Schaff HV, Dearani JA, Sundt TM 3rd, Daly RC, Mullany CJ, et al. Survival advantage and improved durability of mitral repair for leaflet prolapse subsets in the current era. *Ann Thorac Surg*. 2006;82:819-26.
- Adams DH, Anyanwu AC, Rahmanian PB, Abascal V, Salzberg SP, Filsoufi F. Large annuloplasty rings facilitate mitral valve repair in Barlow's disease. *Ann Thorac Surg*. 2006;82:2096-101.
- Maslow AD, Regan MM, Haering JM, Johnson RG, Levine RA. Echocardiographic predictors of left ventricular outflow tract obstruction and systolic anterior motion of the mitral valve after mitral valve reconstruction for myxomatous valve disease. *J Am Coll Cardiol*. 1999;34:2096-104.
- Mihaileanu S, Marino JP, Chauvaud S, Perier P, Forman J, Vissoat J, et al. Left ventricular outflow obstruction after mitral valve repair (Carpentier's technique). Proposed mechanisms of disease. *Circulation*. 1988;78(3 Pt 2):I78-84.
- Jebara VA, Mihaileanu S, Acar C, Brizard C, Grare P, Latremouille C, et al. Left ventricular outflow tract obstruction after mitral valve repair. Results of the sliding leaflet technique. *Circulation*. 1993;88(5 Pt 2):II30-4.
- Deloche A, Jebara VA, Relland JY, Chauvaud S, Fabiani JN, Perier P, et al. Valve repair with Carpentier techniques. The second decade. *J Thorac Cardiovasc Surg*. 1990;99:990-1002.
- Mascagni R, Al Attar N, Lammara M, Calvi S, Tripodi A, Mebazaa A, et al. Edge-to-edge technique to treat post-mitral valve repair systolic anterior motion and left ventricular outflow tract obstruction. *Ann Thorac Surg*. 2005;79:471-4.
- Quigley RL. Prevention of systolic anterior motion after repair of the severely myxomatous mitral valve with an anterior leaflet valvuloplasty. *Ann Thorac Surg*. 2005;80:179-82.
- Bhudia SK, McCarthy PMM, Smedira NG, Lam BK, Rajeswaran J, Blackstone EH. Edge-to-edge (Alfieri) mitral repair: results in diverse clinical settings. *Ann Thorac Surg*. 2004;77:1598-606.
- Civelek A, Szalay Z, Roght M, Arnold R, Klövekom WP, Vogt PR, et al. Post-mitral valve repair systolic anterior motion produced by non-obstructive septal bulge. *Eur J Cardiothorac Surg*. 2003;24:857-61.
- Raney AA, Shah PM, Joyo CI. The 'Pomeroy procedure': a new method to correct post-mitral valve repair systolic anterior motion. *J Heart Valve Dis*. 2001;10:307-11.
- Zegdi R, Carpentier A, Doguet F, Berrebi A, Khabbaz Z, Chauvaud S, et al. Systolic anterior motion after mitral valve repair. *J Thorac Cardiovasc Surg*. 2005;130:1453-4.
- Brown ML, Abel MD, Click RL, Morford RG, Dearani JA, Sundt TM, et al. Systolic anterior motion after mitral valve repair: is surgical intervention necessary? *J Thorac Cardiovasc Surg*. 2007;133:136-43.
- Schiavone WA, Cosgrove DM, Lever HM, Steward WJ, Salcedo EE. Long-term follow-up of patients with left ventricular outflow tract obstruction after Carpentier ring mitral valvuloplasty. *Circulation*. 1998;78(3 Pt 2):I60-5.
- Carpentier AF, Lessana A, Relland JY, Belli E, Mihaileanu S, Berrebi AJ, et al. The "physio-ring": an advanced concept in mitral valve annuloplasty. *Ann Thorac Surg*. 1995;60:1177-86.
- Fornes P, Heudes D, Fuzellier JF, Tixier D, Bruneau P, Carpentier A. Correlation between clinical and histologic patterns of degenerative mitral valve insufficiency: a histomorphometric study of 130 excised segments. *Cardiovasc Pathol*. 1999;8:81-92.
- Gazoni LM, Fedoruk LM, Kern JA, Dent JM, Reece TB, Tribble CG, et al. A simplified approach to degenerative disease: triangular resections of the mitral valve. *Ann Thorac Surg*. 2007;83:1658-65.
- Anyanwu AC, Adams DH. The intraoperative "ink test": a novel assessment tool in mitral valve repair. *J Thorac Cardiovasc Surg*. 2007;133:1635-6.
- Adams DH, Anyanwu AC. Pitfalls and limitations in measuring and interpreting the outcomes of mitral valve repair. *J Thorac Cardiovasc Surg*. 2006;131:523-9.
- Bridgewater B, Hooper T, Munsch C, Hunter S, von Oppell U, Livesey S, et al. Mitral repair best practice: proposed standards. *Heart*. 2006;92:939-44.

Discussion

Dr Aidan A. Raney (*Newport Beach, Calif*). I enjoyed this presentation very much. Dr McCarthy is making a major contribution. As he mentioned, the reparability rate of valves in this country is in the

40% to 50% range. However, if the most complex valves with excessive tissue are included, the overall reparability rate is probably going to be significantly lower, maybe in the 30% range. This device is a tremendous advance. Not only does it simplify the procedure but it also reduces the risk of SAM.

When we looked at our series of over 200 patients about 1½ years ago, we also had about a 5% incidence of SAM that required a second pump run and correction.

I have a few questions for you. In your series, are you repairing all the myxomatous valves with the Myxo-ETlogix ring or do you have a sense of certain valve characteristics that would preclude using this device?

Dr McCarthy. Right now, we look at the leaflet and annulus size. In the majority of these patients with myxomatous leaflets, something is elongated. The valves do not always fall into that category of fibroelastic deficiency, so that it may be an elongated anterior leaflet but not a very elongated posterior, or the other way around. I use the Physio ring when the remaining valve is normal: the anterior leaflet, P1 and P3, are normal, and we have resected the abnormal part, which is usually a flail involving P2.

Dr Raney. Do you think that there is less modification of the annulus with this device, that is, without quadrangular resection and a plication of the posterior annulus? Because sizing can be a problem, do you think that transesophageal echocardiography before the repair will provide a good indication of what size of a Myxo-ETlogix ring to use?

Dr McCarthy. We are collecting a big database on our MV repairs, and we are also going to correlate it with what echocardiography measures. So far, it looks very good. When we measure A2 at 29 mm, the echocardiographer measures it at roughly the same. We hope to get to a point where the echocardiographer can identify the

height of the anterior and posterior leaflets and we can then prescribe the right sized ring.

Dr Raney. We have used this ring now in 8 cases, and I have been very impressed with the efficacy and the efficiency of the ring.

Dr Michael Mack (*Dallas, Tex*). Dr McCarthy, do you have any experience using this ring with artificial chords and does that make sense?

Dr McCarthy. I think it makes sense. I do not really use artificial chords very much. I am still pretty classic and I do chordal transfer. However, some surgeons are using artificial chords with the ring. If artificial chords are used on the posterior leaflet where there is an elongated P2 segment that is not being replaced, I think this would make sense, because otherwise, as you could see from the AP diameter, a 40-mm Physio ring is not nearly big enough for that group of patients.

Dr Mack. Is this ring generally available?

Dr McCarthy. It is in the United States now.

Dr Jen-Ping Chang (*Kaohsiung, Taiwan*). We all know that Professor Carpentier repairs the Barlow valves by banding the septal portion of the classic ring anteriorly, and we know your ring is just like bending the posterior portion of the ring posteriorly. What is the difference between the anterior displacement and the posterior displacement of this ring?

Dr McCarthy. The anterior displacement that Dr Carpentier does periodically is variable: he could bend it just a little bit or he could bend it quite a bit. It seemed to us most of the reduction should be more posterior rather than anterior, and so when we designed the ring, that is where we put it. Also, remember on the classic ring when Dr. Carpentier bends it that way, that is the only place he can bend it because that is where the break is in the ring. So it is the only part that is practical.